

Medical Position Paper

Inflammatory Bowel Disease in Children and Adolescents: Recommendations for Diagnosis—The Porto Criteria

IBD Working Group of the European Society for Paediatric Gastroenterology,
Hepatology and Nutrition (ESPGHAN)

ABSTRACT

Ulcerative colitis and Crohn disease may present before the age of 20 years in 25% to 30% of all patients with inflammatory bowel disease. Reported incidence figures vary considerably depending on the collection of data. Multicenter, multinational collaboration is needed when studying pediatric inflammatory bowel disease. The essential first step is uniformity in the work-up and criteria used for diagnosis. The Porto diagnostic criteria presented here provide the tool that is needed. These criteria are the result of consensus reached by the ESPGHAN inflammatory bowel disease working group. Diagnosis of Crohn disease, ulcerative colitis and indeterminate colitis is based on clinical

signs and symptoms, endoscopy and histology and radiology. Every child suspected of inflammatory bowel disease should undergo a complete diagnostic program consisting of colonoscopy with ileal intubation, upper gastrointestinal endoscopy and (in all cases except in definite ulcerative colitis) radiologic contrast imaging of the small bowel. Multiple biopsies from all segments of the gastrointestinal tract are needed for a complete histologic evaluation. A diagnosis of indeterminate colitis cannot be made unless a full diagnostic program has been performed. *JPGN* 41:1–7, 2005. **Key Words:** IBD—Pediatric—Children—Consensus—Diagnosis—Criteria. © 2005 Lippincott Williams & Wilkins

INTRODUCTION

Ulcerative colitis (UC) and Crohn disease (CD) may present before the age of 20 years in 25% to 30% of all patients with inflammatory bowel disease (IBD) (1). In the pediatric age group, several epidemiologic studies have been published with evidence suggesting that the incidence of IBD (in particular, CD) has increased over the last 10 years (2–7). Both retrospective and prospective studies have been performed in Europe (2–5, 7–21), Australia (6) and the United States (22, 23). The largest study originates from the United Kingdom and Ireland, representing a cohort of 739 children with IBD (17). These studies, summarized in Table 1, show incidence rates of 0.1 (three decades ago) to 4.6 (in the year 2003) per 100,000 children per year for CD and 0.5 to 3.2 (depending on the country reporting) for UC. Comparison between the results of different epidemiologic studies is problematic as the diagnostic criteria, time periods,

design, population size and age groups differ between studies.

Certain features are unique to pediatric IBD as compared with adult onset disease. One feature is growth failure, which is present at diagnosis in 10% to 40% of affected children (24). Less obvious, but nevertheless clinically important, are the differences in clinical presentation that may be the result of different disease location in children compared with adults. In adult series UC is predominantly confined to the rectum or left side of the colon (25, 26), but in children the majority have pan-colitis (20, 23). Abdominal pain is the most frequently seen symptom in children with IBD (20), whereas adults tend to present most often with rectal bleeding (in UC) or diarrhea (in CD). Phenotyping CD according to the Vienna classification into inflammatory, stricturing or fistulizing types (27) may not be useful in children, who have mostly inflammatory disease. Preliminary studies suggest that genetic factors may be of more importance in early onset (pediatric) IBD compared with adult onset IBD (28). A family history of IBD is often present in children (26% to 42%) (29).

The lack of consistent data on the epidemiology, natural course of disease and therapeutic behavior in children with IBD obviates the need for commonly agreed-on diagnostic criteria and work-up of new patients.

Received March 8, 2005; accepted March 9, 2005.

Address correspondence and reprint requests to Dr. Johanna C. Escher, Department of Paediatric Gastroenterology, Erasmus MC – Sophia Children's Hospital, University Medical Center, Dr. Molewaterplein 60, 3015 GJ Rotterdam, The Netherlands. (e-mail: j.escher@erasmusmc.nl).

TABLE 1. Incidence of IBD in children and adolescents per 100,000 children per year

	CD	UC	IC	IBD Total	Data collection
Scotland ⁸	0.7–2.3*	1.5–1.9*	–	–	R
Norway ⁶⁸	2.5	4.3	0	6.8	P
France ⁹	2.1	0.5	0.6	–	P
Sweden ¹⁰	2.6	1.9	0.7	5.3	P
Wales ¹¹	2.2	0.7	–	–	R
Denmark ¹²	0.2	2.0	0	2.2	R
Sweden ¹⁴	1.2	1.4–3.2†	2.2	4.6–7.0†	P
Wales ¹⁵	1.4	0.8	0.5	2.6	P
UK and Ireland ¹⁷	3.0	1.5	0.6	5.2	P
Scotland ³	2.5	1.3	–	–	R
Denmark ⁴	2.3	1.8	0.2	4.3	R
Norway ¹⁹	2.1	2.0	–	–	P
Australia ⁶	0.1–2.0‡	–	–	–	R
USA ²³	4.6	2.1	0.3	7.0	P
Czech Republic ⁷	4.8	2.7	1.8	0.3	R
The Netherlands ²¹	2.1	1.6	3.6	5.2	P
Sweden ⁵	1.7–8.4§	3.3–1.8§	0.2	5.2–10.5§	P

IBD, inflammatory bowel disease; CD, Crohn disease; UC, ulcerative colitis; IC, indeterminate colitis; R, retrospective data collection; P, prospective data collection.

* Incidence numbers for the years 1968 and 1983; † incidence numbers for the years 1984 to 1986 and 1993 to 1995; ‡ incidence numbers rising from 1971 to 2001; § incidence numbers for the years 1990–1992 and 1999–2001.

Adapted from van der Zaag et al.²¹ with permission.

Working Group

The ESPGHAN working group on pediatric IBD epidemiology had its first meeting in Taormina (Sicily, Italy) in June, 2002. A working document with contributions on epidemiologic aspects, clinical and diagnostic criteria, gastrointestinal endoscopy, disease behavior related to treatment response, classification of colitis, genetics, risk factors and future database plans served as a basis for discussion during this meeting.

A second meeting was organized in Porto (Portugal) in March, 2003. Diagnostic criteria and work-up of new patients were discussed and a draft version of the Porto Criteria was obtained. It was decided that a “core database” should be established for prospective registration of essential phenotypic data in new patients. Proceedings of the working group were presented during the ESPGHAN meeting in Prague in June, 2003. The third working group meeting was held in March, 2004 in Porto. In addition to group members from The Netherlands, Denmark, Sweden, United Kingdom, France, Portugal, Italy, Croatia and Israel, ESPGHAN members from Poland, Czech Republic and Germany joined the working group. The final working group consisted of 23 pediatric gastroenterologists from 19 centers in 12 European countries. During the third Porto meeting, group members from various European countries presented national epidemiologic data. Consensus was reached on the final Porto criteria and on the list of phenotypic data

that are required for registration of new IBD patients in a European database.

Aims

Primary aims of the ESPGHAN IBD working group were to define consensus-based criteria for the diagnosis of IBD (CD, UC and indeterminate colitis) in children and to reach agreement on the diagnostic work-up of new pediatric IBD patients. The second aim was to collect uniform phenotypic data on patients (aged 18 years or younger), newly diagnosed with IBD, using the agreed criteria (Porto criteria), based on resources generally available throughout Europe.

The work-up of a child with suspected IBD involves history taking, physical examination, laboratory investigations, endoscopy with biopsies and radiology.

Patient History

A clinical suspicion of IBD is raised in children with persistent (≥ 4 weeks) or recurrent (≥ 2 episodes in 6 months) symptoms such as abdominal pain, diarrhea, rectal bleeding and weight loss. Figure 1 shows the common presenting symptoms prospectively reported in 623 new cases of IBD (20). In this study, the “classic triad” of CD symptoms (abdominal pain, diarrhea and weight loss) was present in a minority (25%) of CD patients. Many young CD patients present in a “non-classic manner” with vague complaints of malaise or mild abdominal discomfort. Other symptoms may be fever, growth retardation, malnutrition, nausea and/or vomiting, psychiatric symptoms, arthropathy, erythema nodosum, secondary amenorrhea, retardation of pubertal development or perianal disease. Extraintestinal manifestations may sometimes dominate the clinical picture especially in CD, causing diagnostic delay. Suspicion of IBD is markedly increased in case of IBD in a first-degree relative.

Physical Examination

To diagnose growth failure, height (including height for age z-score) and weight (including weight for height z-score based on appropriate local distribution) must be recorded at diagnosis and at all subsequent visits. Historical data of height and weight are essential to assess deceleration of growth velocity. Parental height and weight are required to identify the target height of the patient. Pubertal development should be staged according to Tanner (30). Looking for presence of pallor (anemia) and finger clubbing is part of the full examination. The mouth should be examined for lip swelling, gingival hyperplasia or aphthous ulcerations. Skin abnormalities such as vitiligo or extraintestinal manifestations (erythema nodosum, pyoderma gangrenosum) must be recorded. The abdomen is examined for palpable tenderness and abdominal mass (suggestive of ileocecal infiltration or abscess),

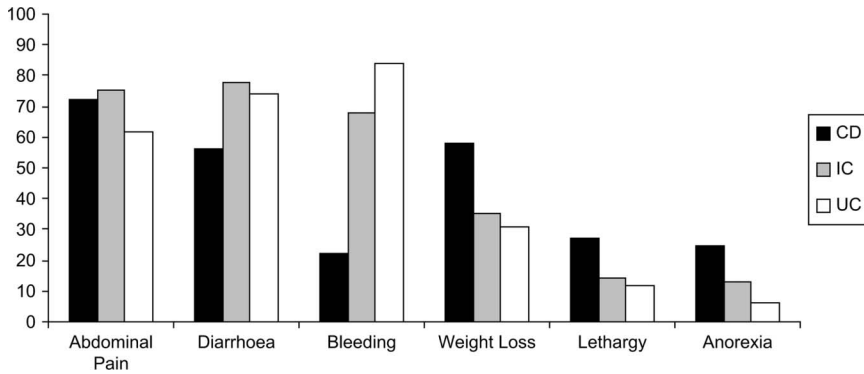


FIG. 1. Presence of symptoms at diagnosis in 623 children with inflammatory bowel disease. Adapted from Sawzchenko et al. (20) with permission.

organomegaly and pain. Examination of the spine may reveal inflammatory back pain as a feature of sacroiliitis. The anal region should be inspected for skin tags, fissures, fistulae or abscesses. In case of arthralgia, the joints should be inspected for arthritis.

Laboratory Examination

Screening blood tests should include full blood count, erythrocyte sedimentation rate, C-reactive protein, serum levels of urea and creatinine, serum albumin, immunoelectrophoresis, liver function tests and (in certain cases) celiac screen. Reduced level of hemoglobin, raised markers of inflammation (erythrocyte sedimentation rate, C-reactive protein), elevated platelet count and reduced serum albumin are suggestive of IBD (31). However, in some UC patients erythrocyte sedimentation rate, hemoglobin and platelet count are found to be normal (32). Elevated platelets may distinguish IBD from infectious diarrhea in a patient presenting with (bloody) diarrhea (33). A recent study has shown that in children suspected of IBD, a combination of anemia and thrombocytosis has a positive predictive value of 90% for IBD and a negative predictive value of 81% (32). Presence of anti-*Saccharomyces cerevisiae* antibody or anti-neutrophil cytoplasmic antibody raises the suspicion for a diagnosis of CD or UC, respectively. The diagnostic sensitivity of these serological markers ranges between 60% and 80% (34–37).

Infectious causes of enteritis or colitis should be excluded by stool cultures (for *Salmonella*, *Shigella*, *Yersinia*, *Campylobacter* and *Clostridium difficile*), and stool tests for *Clostridium difficile* toxins A and B, *Giardia lamblia* and *Entamoeba histolytica* (parasites, cysts and ova or direct microscopy for trophozoites in case of severe bloody diarrhea in patients having travelled to areas with endemic occurrence of amebic dysentery). Identification of a pathogen however does not necessarily exclude a diagnosis of IBD, as a first episode of IBD may present after documented enteric infection. In children in a population at risk from tuberculosis, this should be included in the differential diagnosis.

Endoscopy and Histology

Colonoscopy including intubation of the terminal ileum and multiple biopsies for histology obtained from all segments of the lower intestinal tract (ileum, cecum, ascending colon, transverse colon, descending colon, sigmoid and rectum) is essential; it is the most important investigation to differentiate between CD and ulcerative colitis and identifies localization and extent of inflammatory disease (38). Intubation of the terminal ileum with terminal ileum biopsies should always be attempted, as isolated ileal inflammation may occur in the presence of a normal colon in up to 9% of children with CD (20). Examination of the small bowel by small bowel follow through without ileocolonoscopy is insufficient, as the radiologic examination may give a negative result when the inflammatory changes are subtle (39). In addition, visualization of the ileum and ileal biopsies are crucial in the differential diagnosis of patients with pancolitis (40). Rectosigmoidoscopy alone is insufficient, as proximal abnormalities can only be assessed by full colonoscopy (41, 42).

Upper endoscopy is advocated in all children irrespective of presence or absence of upper gastrointestinal symptoms. Thus, gastric or duodenal pathology such as ulcers may be identified and biopsies can be obtained. Histology of the upper gastrointestinal tract (showing specific lesions such as giant cell granulomas or aphthoid ulcers) may confirm a diagnosis of CD that would otherwise have been missed in 11% to 29% of cases (43–45). As an isolated finding, focally enhanced gastritis, often reported to be suggestive of CD, is neither sensitive nor specific for IBD (46, 47). Contrary to the earlier views, nonspecific inflammation in the upper gastrointestinal tract may co-exist in up to 75% of children with UC (45, 46, 48–50).

In children, it is preferable if endoscopy is performed under general anesthesia or deep sedation (51–53).

Table 2 summarizes diagnostic findings during endoscopy and histology for CD and UC. CD may present anywhere in the gastrointestinal tract, but rectal sparing is common. In UC the disease is localized in the colon, with inflammation extending from rectum to proximal

TABLE 2. Endoscopy and histology in inflammatory bowel disease

	Crohn disease	Ulcerative colitis
Endoscopy (and visualization of oral and/or perianal regions)	Ulcers (aphthous, linear, or stellate) Cobblestoning Skip lesions Strictures Fistula Abnormalities in oral and/or perianal regions Segmental distribution	Ulcers Erythema Loss of vascular pattern granularity Friability Spontaneous bleeding Pseudopolyps Continuous with variable proximal extension from rectum
Histology	Submucosal (biopsy with sufficient submucosal tissue) or transmural involvement (surgical specimen) Ulcers, crypt distortion Crypt abscess Granulomas (non-caseating, nonmucin) Focal changes (within biopsy) Patchy distribution (biopsies)	Mucosal involvement Crypt distortion Crypt abscess Goblet cell depletion Mucin granulomas (rare) Continuous distribution

Histology for both Crohn disease and ulcerative colitis included acute and chronic inflammation with architectural changes, loss of glands, and branching of crypts. Crohn disease abnormalities in oral region included lip swelling, gingival hyperplasia, aphthous ulcers; Crohn disease abnormalities in perianal region included tags, fissures, fistulae, and abscess.

colon. However, several authors have recently described rectal sparing in untreated children with UC (54–56). Indeterminate colitis can only be diagnosed after a full diagnostic work-up. This must include colonoscopy with intubation of the terminal ileum, upper gastrointestinal endoscopy and small bowel follow through. Diagnosis of indeterminate colitis is suggested by histology showing acute and chronic inflammation with architectural changes confined to the colon, absence of abnormalities suggesting lymphocytic or allergic colitis, or CD, a normal small bowel follow through or enteroclysis and no definite classification of CD or UC possible with histology (57). Capsule endoscopy may be used to identify small bowel lesions (once a stricture has been excluded) but cannot replace endoscopy because of the need to define disease on the basis of histology (58, 59).

Radiology

The finding of a normal terminal ileum on ileoscopy does not render radiologic examination of the small bowel obsolete. The small bowel may be abnormal even though the terminal ileum is normal (60, 61). In addition, small bowel follow through or enteroclysis with intubation of the duodenum with barium contrast will give information on extent and possible complications of small bowel involvement in CD including stenosis, stricture or internal fistulae. The presence of small bowel stenosis will affect therapeutic management, as inactive short segment stenosis may need resection. Other radiologic features suggestive of active CD are cobblestoning, ulceration, separation of bowel loops and segmental distribution with skip lesions (60, 61).

Barium enema is useful in case of stenosis when the colon has not been visualized completely by endoscopy.

Transabdominal ultrasound is noninvasive and may reveal intestinal or colonic wall thickening or infiltrate but will not show subtle inflammatory changes (62–64). Leukocyte scintigraphy has been proposed as a noninvasive screening test but has been found to have insufficient diagnostic sensitivity (62, 65). Gadolinium-enhanced magnetic resonance imaging or magnetic resonance imaging enteroclysis may prove to be more sensitive and specific tools for diagnosing small bowel CD, but more validation studies are needed in children (66, 67). 68

Summary of ESPGHAN Diagnostic Criteria for Diagnosis of IBD (Porto Criteria)

Figure 2 shows a summary of the Porto criteria for the diagnosis of IBD. Children and adolescents with symptoms suggestive of IBD should be referred to a pediatric gastroenterologist for diagnostic work-up. Infectious causes of (bloody) diarrhea is to be excluded and laboratory screening tests should be performed. All patients

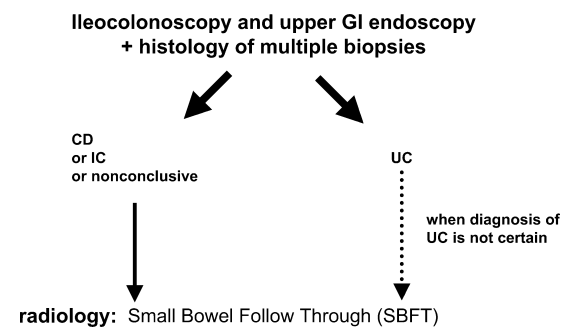


FIG. 2. Porto criteria for diagnosis of inflammatory bowel disease in children.

have to undergo endoscopic evaluation (ileocolonoscopy and upper gastrointestinal endoscopy). During endoscopy, biopsies (of inflamed and non-inflamed mucosa) should be taken from each segment of the gastrointestinal tract. Biopsies may be multiple in selected areas, with each biopsy site precisely recorded. The combination of clinical symptoms with endoscopic and histologic findings described in Table 2 will enable a diagnosis of the type of IBD: CD or UC. A diagnosis of indeterminate colitis is acceptable only when the diagnostic program has been fully completed. Except in cases where a definite diagnosis of UC is made (on the basis of endoscopy and histology), radiologic evaluation of the small bowel (small bowel follow through or enteroclysis) is mandatory. In case of incomplete ileocolonoscopy as the result of technical difficulties, an attempt should be made to complete the work-up by repeat ileocolonoscopy in patients with suspected CD or when the type of inflammatory colitis can not be determined. When colonic stricturing exists, radiologic investigation (barium enema or technetium leukocyte scan) may be helpful in defining the extent of the disease.

Future Plans

Current validation of the Porto diagnostic criteria presented here and further collaborative studies by the group are described in the Appendix.

Concluding Remarks

Collection of information on disease expression at presentation, characteristics during the course of disease, potential predisposing factors, extraintestinal manifestations, treatment course, surgery and outcome will generate knowledge about early onset inflammatory bowel disease. The essential first step is uniformity in the work-up and criteria used for diagnosis. The Porto diagnostic criteria presented here provide the tool that is needed.

REFERENCES

- Mamula P, Markowitz JE, Baldassano RN. Inflammatory bowel disease in early childhood and adolescence: special considerations. *Gastroenterol Clin North Am* 2003;32:967-95.
- Askling J, Grahnquist L, Ekblom A, Finkel Y. Incidence of paediatric Crohn's disease in Stockholm, Sweden. *Lancet* 1999; 354:1179.
- Armitage E, Drummond HE, Wilson DC, Ghosh S. Increasing incidence of both juvenile-onset Crohn's disease and ulcerative colitis in Scotland. *Eur J Gastroenterol Hepatol* 2001;13:1439-47.
- Urne FU, Paerregaard A. Chronic inflammatory bowel disease in children. An epidemiological study from eastern Denmark 1998-2000 [in Danish]. *Ugeskr Laeger* 2002;164:5810-4.
- Hildebrand H, Finkel Y, Grahnquist L, et al. Changing pattern of paediatric inflammatory bowel disease in northern Stockholm 1990-2001. *Gut* 2003;52:1432-4.
- Phavichitr N, Cameron DJ, Catto-Smith AG. Increasing incidence of Crohn's disease in Victorian children. *J Gastroenterol Hepatol* 2003;18:329-32.
- Kolek A, Janout V, Tichy M, Grepl M. The incidence of inflammatory bowel disease is increasing among children 15 years old and younger in the Czech Republic. *J Pediatr Gastroenterol Nutr* 2004;38:362-3.
- Barton JR, Gillon S, Ferguson A. Incidence of inflammatory bowel disease in Scottish children between 1968 and 1983; marginal fall in ulcerative colitis, three-fold rise in Crohn's disease. *Gut* 1989;30: 618-22.
- Gottrand F, Colombel JF, Moreno L, Salomez JL, Farriaux JP, Cortot A. Incidence of inflammatory bowel diseases in children in the Nord-Pas-de-Calais region [in French]. *Arch Fr Pediatr* 1991;48:25-8.
- Hildebrand H, Brydolf M, Holmquist L, Krantz I, Kristiansson B. Incidence and prevalence of inflammatory bowel disease in children in south-western Sweden. *Acta Paediatr* 1994;83:640-5.
- Cosgrove M, Al-Atia RF, Jenkins HR. The epidemiology of paediatric inflammatory bowel disease. *Arch Dis Child* 1996;74:460-1.
- Langholz E, Munkholm P, Krasilnikoff PA, Binder V. Inflammatory bowel diseases with onset in childhood: Clinical features, morbidity, and mortality in a regional cohort. *Scand J Gastroenterol* 1997;32: 139-47.
- Armitage E, Drummond H, Ghosh S, Ferguson A. Incidence of juvenile-onset Crohn's disease in Scotland. *Lancet* 1999;353:1496-7.
- Lindberg E, Lindquist B, Holmquist L, Hildebrand H. Inflammatory bowel disease in children and adolescents in Sweden, 1984-1995. *J Pediatr Gastroenterol Nutr* 2000;30:259-64.
- Hassan K, Cowan FJ, Jenkins HR. The incidence of childhood inflammatory bowel disease in Wales. *Eur J Pediatr* 2000;159:261-3.
- Tourteliery Y, Dabadie A, Tron I, et al. Incidence of inflammatory bowel disease in children in Brittany (1994-1997). Breton association of study and research on digestive system diseases (Abermad) [in French]. *Arch Pediatr* 2000;7:377-84.
- Sawczenko A, Sandhu BK, Logan RF, et al. Prospective survey of childhood inflammatory bowel disease in the British Isles. *Lancet* 2001;357:1093-4.
- Card TR, Sawczenko A, Sandhu BK, Logan RF. No seasonality in month of birth of inflammatory bowel disease cases: a prospective population based study of British under 20 year olds. *Gut* 2002;51: 814-5.
- Bentsen BS, Moum B, Ekblom A. Incidence of inflammatory bowel disease in children in southeastern Norway: a prospective population-based study 1990-94. *Scand J Gastroenterol* 2002;37:540-5.
- Sawczenko A, Sandhu BK. Presenting features of inflammatory bowel disease in Great Britain and Ireland. *Arch Dis Child* 2003;88: 995-1000.
- van der Zaag-Loonen HJ, Casparie M, Taminiou JA, et al. The incidence of pediatric inflammatory bowel disease in the Netherlands: 1999-2001. *J Pediatr Gastroenterol Nutr* 2004;38:302-7.
- Ogunbi SO, Ransom JA, Sullivan K, Schoen BT, Gold BD. Inflammatory bowel disease in African-American children living in Georgia. *J Pediatr* 1998;133:103-7.
- Kugathasan S, Judd RH, Hoffmann RG, et al. Epidemiologic and clinical characteristics of children with newly diagnosed inflammatory bowel disease in Wisconsin: a statewide population-based study. *J Pediatr* 2003;143:525-31.
- Motil KJ, Grand RJ, Davis-Kraft L, Ferlic LL, Smith EO. Growth failure in children with inflammatory bowel disease: a prospective study. *Gastroenterology* 1993;105:681-91.
- Farmer RG, Easley KA, Rankin GB. Clinical patterns, natural history, and progression of ulcerative colitis: A long-term follow-up of 1116 patients. *Dig Dis Sci* 1993;38:1137-46.
- Rubin GP, Hungin AP, Kelly PJ, Ling J. Inflammatory bowel disease: epidemiology and management in an English general practice population. *Aliment Pharmacol Ther* 2000;14:1553-9.
- Gasche C, Scholmerich J, Brynskov J, et al. A simple classification of Crohn's disease: report of the Working Party for the World Congresses of Gastroenterology, Vienna 1998. *Inflamm Bowel Dis* 2000;6:8-15.
- Sun L, Roesler J, Rosen-Wolff A, et al. CARD15 genotype and phenotype analysis in 55 pediatric patients with Crohn disease from Saxony, Germany. *J Pediatr Gastroenterol Nutr* 2003;37:492-7.

29. Weinstein TA, Levine M, Pettei MJ, et al. Age and family history at presentation of pediatric inflammatory bowel disease. *J Pediatr Gastroenterol Nutr* 2003;37:609–13.
30. Tanner J. Growth at adolescence. Oxford: Blackwell Scientific, 1962.
31. Beattie RM, Walker-Smith JA, Murch SH. Indications for investigation of chronic gastrointestinal symptoms. *Arch Dis Child* 1995;73: 354–5.
32. Cabrera-Abreu JC, Davies P, Matek Z, Murphy MS. Performance of blood tests in diagnosis of inflammatory bowel disease in a specialist clinic. *Arch Dis Child* 2004;89:69–71.
33. Harries AD, Beeching NJ, Rogerson SJ, Nye FJ. The platelet count as a simple measure to distinguish inflammatory bowel disease from infective diarrhoea. *J Infect* 1991;22:247–50.
34. Olives JP, Breton A, Hugot JP, et al. Antineutrophil cytoplasmic antibodies in children with inflammatory bowel disease: prevalence and diagnostic value. *J Pediatr Gastroenterol Nutr* 1997;25:142–8.
35. Ruemmele FM, Targan SR, Levy G, et al. Diagnostic accuracy of serological assays in pediatric inflammatory bowel disease. *Gastroenterology* 1998;115:822–9.
36. Hoffenberg EJ, Fidanza S, Sauaia A. Serologic testing for inflammatory bowel disease. *J Pediatr* 1999;134:447–52.
37. Khan K, Schwarzenberg SJ, Sharp H, Greenwood D, Weisdorf-Schindele S. Role of serology and routine laboratory tests in childhood inflammatory bowel disease. *Inflamm Bowel Dis* 2002;8: 325–9.
38. Griffiths AMB, Büller HA. Inflammatory bowel disease. In: Walker WA, Durie PR, Hamilton, JR, Walker-Smith JA, Watkins JB, eds. *Pediatric Gastrointestinal Disease: Pathophysiology, Diagnosis, Management*. Hamilton: BC Decker Inc, 2000:613–51.
39. Batres LA, Maller ES, Ruchelli E, Mahboubi S, Baldassano RN. Terminal ileum intubation in pediatric colonoscopy and diagnostic value of conventional small bowel contrast radiography in pediatric inflammatory bowel disease. *J Pediatr Gastroenterol Nutr* 2002;35: 320–3.
40. Geboes K, Ectors N, D'Haens G, Rutgeerts P. Is ileoscopy with biopsy worthwhile in patients presenting with symptoms of inflammatory bowel disease? *Am J Gastroenterol* 1998;93:201–6.
41. Holmquist L, Rudic N, Ahren C, Fallstrom SP. The diagnostic value of colonoscopy compared with rectosigmoidoscopy in children and adolescents with symptoms of chronic inflammatory bowel disease of the colon. *Scand J Gastroenterol* 1988;23:577–84.
42. Escher JC, ten KF, Lichtenbelt K, et al. Value of rectosigmoidoscopy with biopsies for diagnosis of inflammatory bowel disease in children. *Inflamm Bowel Dis* 2002;8:16–22.
43. Castellaneta SP, Afzal NA, Greenberg M, et al. Diagnostic role of upper gastrointestinal endoscopy in pediatric inflammatory bowel disease. *J Pediatr Gastroenterol Nutr* 2004;39:257–61.
44. Mashako MN, Cezard JP, Navarro J, et al. Crohn's disease lesions in the upper gastrointestinal tract: correlation between clinical, radiological, endoscopic, and histological features in adolescents and children. *J Pediatr Gastroenterol Nutr* 1989;8:442–6.
45. Abdullah BA, Gupta SK, Croffie JM, et al. The role of esophago-gastroduodenoscopy in the initial evaluation of childhood inflammatory bowel disease: a 7-year study. *J Pediatr Gastroenterol Nutr* 2002;35:636–40.
46. Sharif F, McDermott M, Dillon M, et al. Focally enhanced gastritis in children with Crohn's disease and ulcerative colitis. *Am J Gastroenterol* 2002;97:1415–20.
47. Xin W, Greenson JK. The clinical significance of focally enhanced gastritis. *Am J Surg Pathol* 2004;28:1347–51.
48. Ruuska T, Vaajalahti P, Arajärvi P, Maki M. Prospective evaluation of upper gastrointestinal mucosal lesions in children with ulcerative colitis and Crohn's disease. *J Pediatr Gastroenterol Nutr* 1994;19: 181–6.
49. Tobin JM, Sinha B, Ramani P, Saleh AR, Murphy MS. Upper gastrointestinal mucosal disease in pediatric Crohn disease and ulcerative colitis: a blinded, controlled study. *J Pediatr Gastroenterol Nutr* 2001;32:443–8.
50. Kundhal PS, Stormon MO, Zachos M, et al. Gastral antral biopsy in the differentiation of pediatric colitides. *Am J Gastroenterol* 2003; 98:557–61.
51. Dillon M, Brown S, Casey W, et al. Colonoscopy under general anesthesia in children. *Pediatrics* 1998;102:381–3.
52. Elitsur Y, Blankenship P, Lawrence Z. Propofol sedation for endoscopic procedures in children. *Endoscopy* 2000;32:788–91.
53. Wengrower D, Gozal D, Gozal Y, et al. Complicated endoscopic pediatric procedures using deep sedation and general anesthesia are safe in the endoscopy suite. *Scand J Gastroenterol* 2004;39: 283–6.
54. Markowitz J, Kahn E, Grancher K, Hyams J, Treem W, Daum F. Atypical rectosigmoid histology in children with newly diagnosed ulcerative colitis. *Am J Gastroenterol* 1993;88:2034–7.
55. Rajwal SR, Puntis JW, McClean P, et al. Endoscopic rectal sparing in children with untreated ulcerative colitis. *J Pediatr Gastroenterol Nutr* 2004;38:66–9.
56. Glickman JN, Bousvaros A, Farraye FA, et al. Pediatric patients with untreated ulcerative colitis may present initially with unusual morphologic findings. *Am J Surg Pathol* 2004;28:190–7.
57. Chong SK, Blackshaw AJ, Boyle S, Williams CB, Walker-Smith JA. Histological diagnosis of chronic inflammatory bowel disease in childhood. *Gut* 1985;26:55–9.
58. Seidman EG, Sant'Anna AM, Dirks MH. Potential applications of wireless capsule endoscopy in the pediatric age group. *Gastrointest Endosc Clin N Am* 2004;14:207–17.
59. Mow WS, Lo SK, Targan SR, et al. Initial experience with wireless capsule enteroscopy in the diagnosis and management of inflammatory bowel disease. *Clin Gastroenterol Hepatol* 2004;2:31–40.
60. Lipson A, Bartram CI, Williams CB, Slavin G, Walker-Smith J. Barium studies and ileoscopy compared in children with suspected Crohn's disease. *Clin Radiol* 1990;41:5–8.
61. Halligan S, Nicholls S, Beattie RM, et al. The role of small bowel radiology in the diagnosis and management of Crohn's disease. *Acta Paediatr* 1995;84:1375–8.
62. Alberini JL, Badran A, Freneaux E, et al. Technetium-99m HMPAO-labeled leukocyte imaging compared with endoscopy, ultrasonography, and contrast radiology in children with inflammatory bowel disease. *J Pediatr Gastroenterol Nutr* 2001;32:278–86.
63. Bremner AR, Pridgeon J, Fairhurst J, Beattie RM. Ultrasound scanning may reduce the need for barium radiology in the assessment of small-bowel Crohn's disease. *Acta Paediatr* 2004;93:479–81.
64. Haber HP, Stern M. Intestinal ultrasonography in children and young adults: bowel wall thickness is age dependent. *J Ultrasound Med* 2000;19:315–21.
65. Davison SM, Chapman S, Murphy MS. 99mTc-HMPAO leucocyte scintigraphy fails to detect Crohn's disease in the proximal gastrointestinal tract. *Arch Dis Child* 2001;85:43–6.
66. Laghi A, Borrelli O, Paolantonio P, et al. Contrast enhanced magnetic resonance imaging of the terminal ileum in children with Crohn's disease. *Gut* 2003;52:393–7.
67. Darbari A, Sena L, Argani P, Oliva-Hemker JM, Thompson R, Cuffari C. Gadolinium-enhanced magnetic resonance imaging: a useful radiological tool in diagnosing pediatric IBD. *Inflamm Bowel Dis* 2004;10:67–72.
68. Olafsdottir EJ, Fluge G, Haug K. Chronic inflammatory bowel disease in children in western Norway. *J Pediatr Gastroenterol Nutr* 1989;8:454–8.

APPENDIX

Audit of Porto Criteria

To audit the Porto Criteria, the group has started to prospectively collect anonymous data on new IBD patients from the participating centres from May 1, 2004 using an agreed database sheet (available on request from

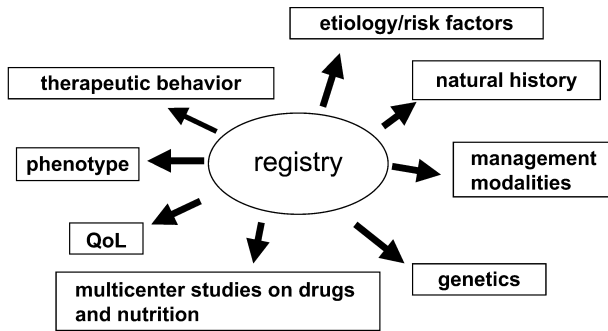


FIG 3. Core database and future studies in children with inflammatory bowel disease.

corresponding author). For each center in each country, approval was sought from the local Ethics Committee. In most countries, the Ethics Committee and/or Registration office for databases released a statement of no objection because the data are anonymous. Only in the United Kingdom, Sweden and Poland, was full review by the local Ethics Committee required. Data registration is currently ongoing until May 1, 2005, when it will be audited.

A compact database of prospectively collected pediatric IBD patients will serve as a nucleus for investigators studying genetics, drug therapy, health outcomes, and the socioeconomic impact of these diseases. The ultimate goal envisioned by the working group is to perform several collaborative European studies on this unique cohort of uniformly phenotyped patients gathered in a core data-

base (Fig. 3). This large and well-organized database will greatly facilitate the collection of sufficient amounts of human material (specimens), enabling research on the etiology and pathophysiology of early onset IBD.

J. C. Escher
 J. Amil Dias
 K. Bochenek
 S. Buderus
 M. Bueno de Mesquita
 Y. Bujanover
 H. A. Büller
 S. K. F. Chong
 S. Cucchiara
 J. M. E. Fell
 J. Henker
 H. Hildebrand
 J. P. Hugot
 U. Jedynak
 H. Jenkins
 S. Kolacek
 S. Koletzko
 I. Lazowska
 A. Levine
 P. Lionetti
 J. Maly
 S. M. Montgomery
 S. H. Murch
 M. S. Murphy
 A. Paerregaard
 B. K. Sandhu
 A. Sawczenko